

Neuromuscular Orthodontic Correction of a Class III Patient

Fabio Savastano* and Giulia Savastano

International College of Neuromuscular Orthodontics and Gnathology (ICNOG), Piazza Berlinguer 14, Albenga (SV), Italy

***Corresponding Author:** Fabio Savastano, International College of Neuromuscular Orthodontics and Gnathology, Piazza Berlinguer 14, Albenga (SV), Italy.

Received: June 05, 2020; **Published:** September 15, 2020

Abstract

Introduction: Patients with a skeletal Class III pattern without reverse overjet may show signs and symptoms of temporomandibular joint (TMJ) overload. Orthodontic correction should be performed while paying particular attention to TMJ preservation. Mandibular tracking and surface electromyography (SEMG) are essential aids for diagnostic and follow-up procedures.

Aim: To apply neuromuscular dentistry principles to the orthodontic treatment of skeletal Class III patients with signs and symptoms of TMJ disfunction.

Methods: The diagnostic and follow-up procedures were based on the use of mandibular tracking (computerized mandibular scanning), SEMG and transcutaneous electrical nerve stimulation.

Results: After treatment and at 10.5 years follow-up, there were no TMD signs or symptoms.

Conclusion: Neuromuscular orthodontics is an effective diagnostic procedure that can assist the orthodontist in correcting malocclusions related to TMJ disorders.

Keywords: *Neuromuscular Orthodontics; Transcutaneous Electrical Nerve Stimulator; Mandibular Posture; Mandibular Kinesiograph; Surface Electromyography*

Abbreviations

CMS: Computerized Mandibular Scanning; EMG: Electromyography; Ni-Ti: Nickel-Titanium; SEMG: Surface Electromyography; TENS: Transcutaneous Electrical Nerve Stimulation; TMJ: Temporomandibular Joint

Introduction

A major topic of debate in orthodontics is the most appropriate treatment of Class III skeletal patients without reverse overjet. Some of these patients show signs and symptoms of TMJ dysfunction; the main factor in this type of malocclusion is the skeletal discrepancy. The lower incisors are usually tipped lingually, and a Class III dental occlusion is sometimes observed. The mandible is positioned distally in centric occlusion, resulting in a posterior dislocated condyle. This temporomandibular joint (TMJ) overload can be observed clinically on the first visit, characterized by clicks during aperture and other signs of TMJ dysfunction, such as pain and dysphagia. Posterior condylar displacement is the most frequent cause of TMJ dysfunction and can be observed at all ages [1-10]. In some cases, patients are referred directly to TMJ specialists because of joint pain. Some cases are so severe that surgical repositioning of the mandible or the maxilla is the only option.

So how can we measure this skeletal discrepancy and quantify the TMJ overload? Indeed, orthodontists' main goal is to plan an orthodontic procedure knowing that, at end of treatment, there will be no TMJ overload. Unfortunately, some of these delicate cases are diagnosed inadequately, leading the practitioner to create a beautiful occlusion instead of a functional one. On the other hand, even the best diagnostic methods must deal with factors such as growth, patient compliance, and the practitioner's ability. A neuromuscular approach might be the answer to such demanding issues since it uses bioelectrical instrumentation, including the mandibular kinesiograph (or computerized mandibular scanning [CMS]), surface electromyography (SEMG), and transcutaneous electrical nerve stimulation (TENS).

Mandibular range and motion was recorded using the K7 Evaluation System (Myotronics-Noromed, Inc., Kent, WA, USA). This device includes the K7/Computerized Mandibular Scanner (CMS), the K7/Electromyograph (EMG), and the K7/Electrosonograph (ESG; for joint sound recording) and is regularly checked and calibrated at two-year intervals. This system allows mandibular movements and function to be evaluated simultaneously. The software allows the clinician to evaluate electromyographically selected muscles during mandibular movements, such as clenching or mouth opening.

The J4 Myomonitor TENS unit (Myotronics-Noromed, Inc.) was used in the study. The J4 is a low-frequency TENS device that delivers bilateral electrical stimulation of the trigeminal (V) and facial (VII) cranial nerves when electrodes are placed bilaterally on the coronoid notch. A third electrode, the neutral electrode, is placed at equal distance from the first two, behind the lower neck. This system unfolds the individual physiological requests that lead to the recording of the ideal mandibular-cranium relationship, thus providing the practitioner with precious information that can be used for treatment planning [11-26].

Case Report

Diagnosis and etiology

In November 2004, an 11-year-old boy presented to my office for orthodontic treatment of misaligned teeth and bilateral joint pain during mastication. He had a flat profile and large lips.

The intraoral examination showed healthy periodontal tissues and some signs of excess oral hygiene and brushing. A slight deep bite was accompanied by lower anterior crowding due to lingually tipped incisors. There was a Class III dental occlusion on both sides and crossbite of the upper first left premolar and lower left canine (Figure 1A-1E).

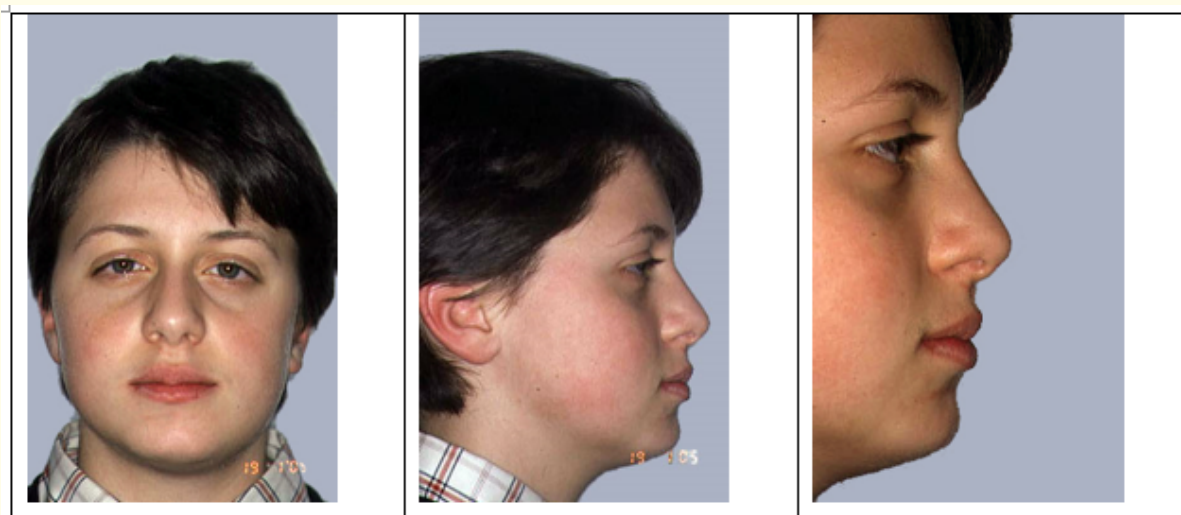


Figure 1A: Front, lateral, and profile photos pre-treatment.

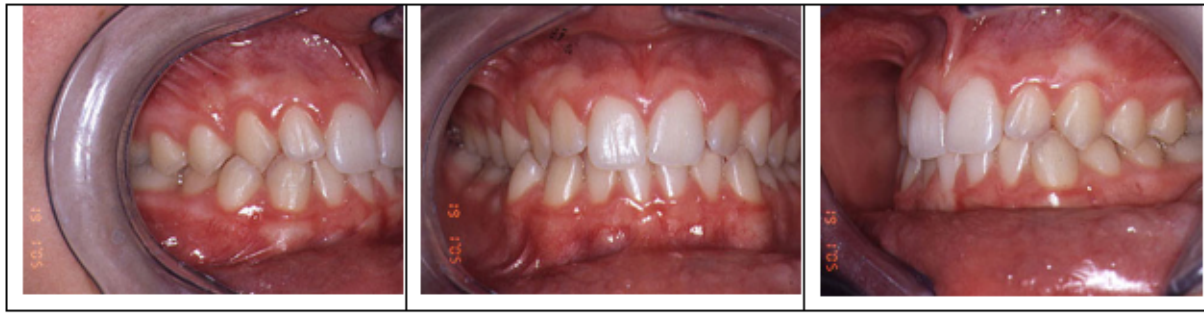

Figure 1B: Intra-oral photos pre-treatment. From left to right, upper lateral right, center, upper lateral left.

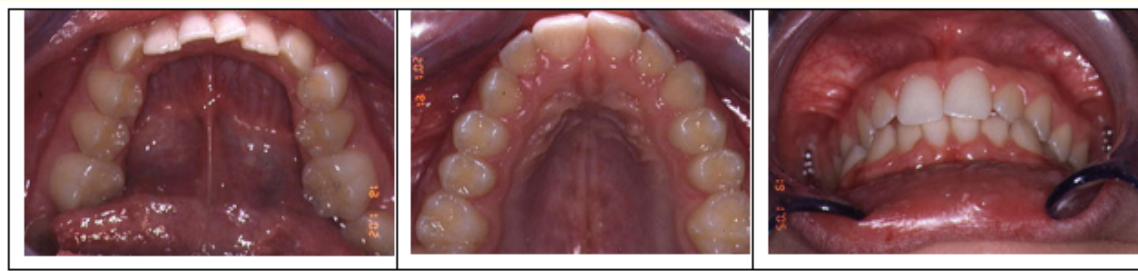

Figure 1C: Intra-oral photos pre-treatment. From left to right, lower occlusal upper occlusal, center showing incisal contact.

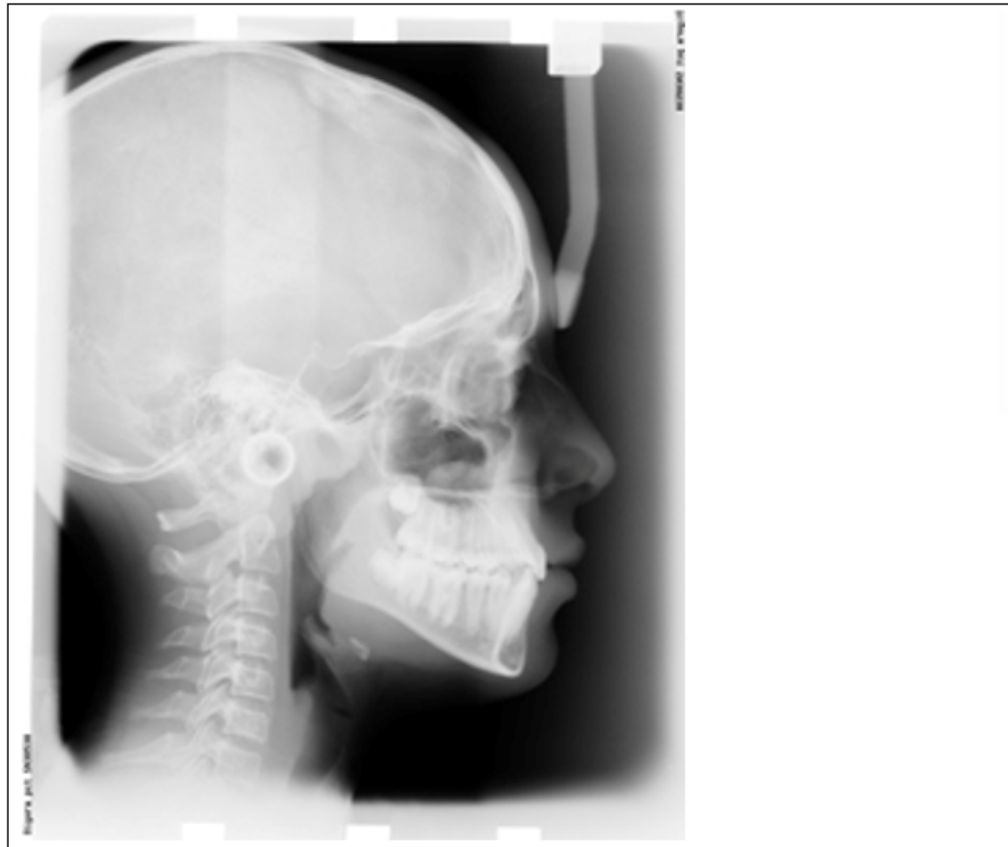

Figure 1D: Pre-treatment lateral cephalometric radiograph.

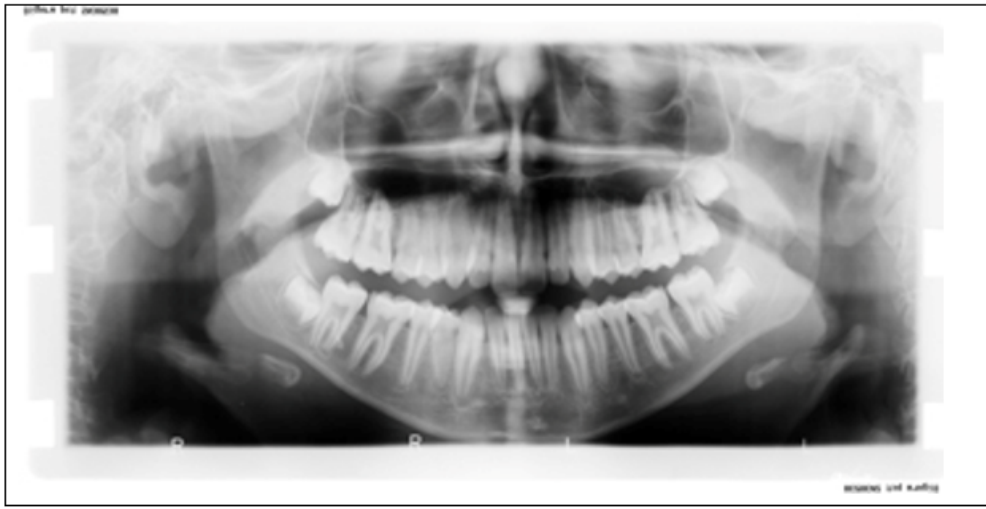

Figure 1E: Pre-treatment panoramic X-ray.

Treatment objectives

The treatment objectives were to correct the molar relationship and lower crowding without compromising TMJ function. TMJ pain and symptoms were major concerns. Forward positioning of the mandible was calculated with respect to residual mandibular growth and space for lower anterior incisor alignment.

Treatment alternatives

The treatment options included the following:

1. No treatment
2. Surgery
3. Non-extraction treatment.

TMJ pain was the patient's main complaint. All treatment alternatives were refused, except for non-extraction treatment. The patient was aware that there was a concrete possibility of incomplete recovery from TMJ pain.

Treatment progress

By January 2005, complete records were obtained, and a complete functional analysis was subsequently performed to assess skeletal discrepancy.

Treatment was initiated in February 2005 with a rapid maxillary expander, one activation/day, and face mask for a minimum of 12 hours a day. After expansion was complete, the upper arch for initial alignment was bonded using a 0.014-in. nickel-titanium (Ni-Ti) alloy archwire, followed by a 0.017 × 0.025-in. copper Ni-Ti. The rapid maxillary expander was removed in May 2005. Alignment of the upper arch was stabilized with a 0.018 x 0.025-in. stainless steel archwire in December 2005. Class III elastics (1/4 4.5 oz.) were worn 16 hours/

day from April 2006 to June 2006. The lower arch was bonded in March 2006, using an archwire sequence of 0.014-in. copper Ni-Ti, 0.016 x 0.016-in. copper Ni-Ti, and 0.016 x 0.22-in. stainless steel.

Treatment was terminated on August 6, 2006. The patient was debonded, and a fixed lower intercanine composite retention was applied. Upper removable retention was prescribed for 16 hours/day.

Treatment results

A complete remission of TMJ signs and symptoms was noted after maxillary expansion and initial alignment of the upper arch. A Class I dental occlusion and alignment of the lower incisors were obtained. The patient experienced no further TMJ pain or signs, including clicking during aperture. No other discomfort related to malocclusion was present (e.g. muscle tenderness, reduction of opening, dysphagia) (Figure 2A-2F).

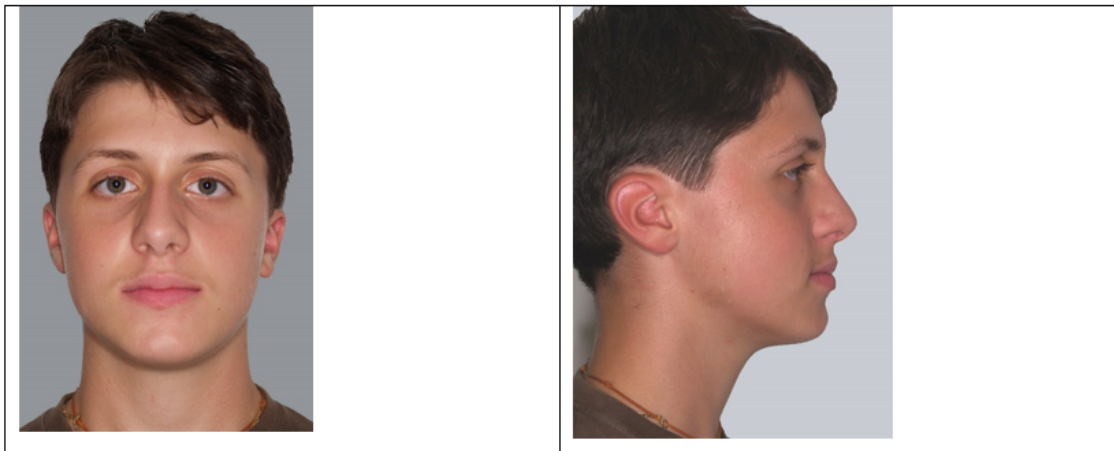


Figure 2A: Front and lateral profile after treatment.

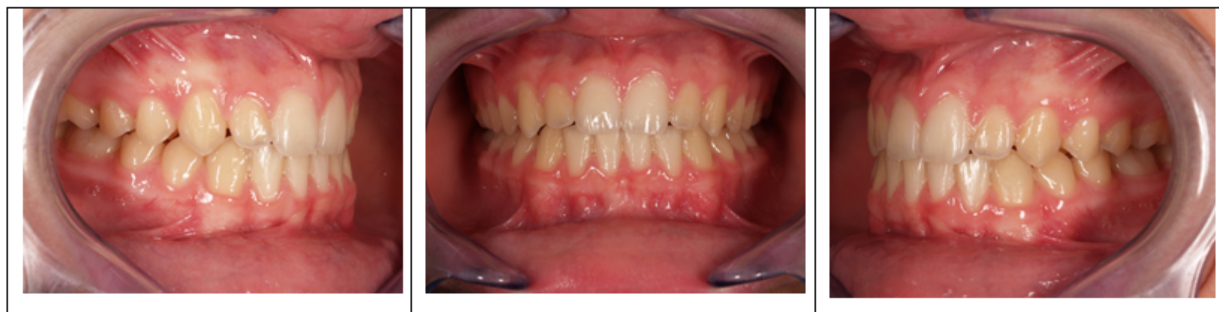

Figure 2B: Intra-oral photos after treatment, lateral right, center, lateral left.

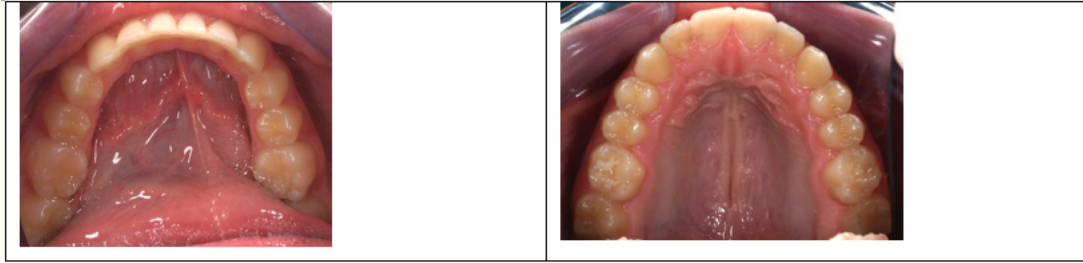


Figure 2C: Intra-oral occlusal photos after treatment, lower arch, upper arch.

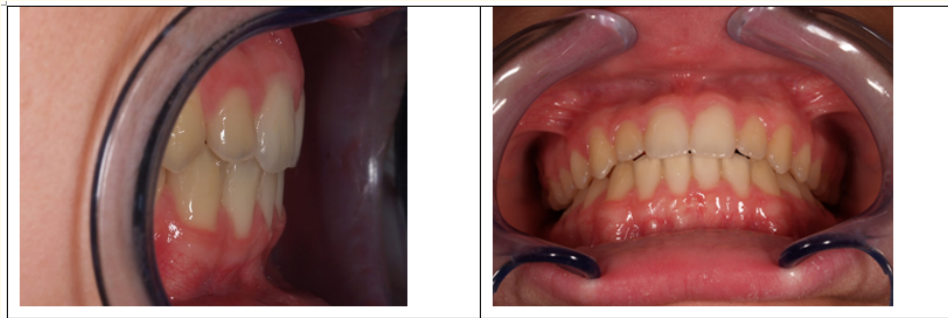


Figure 2D: Overjet after treatment.

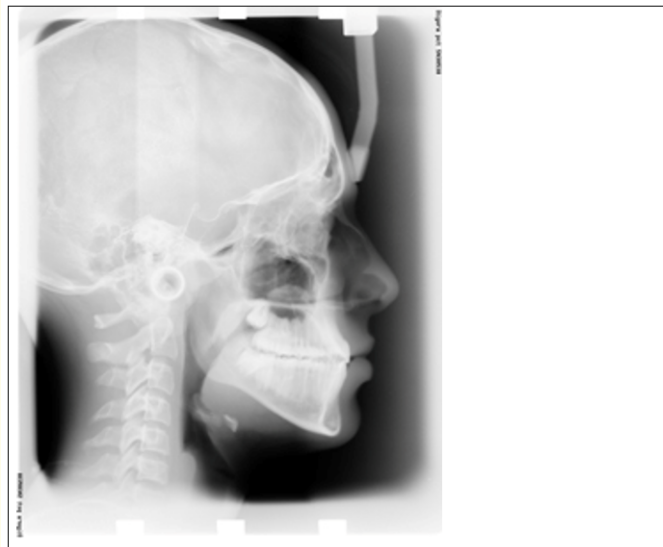

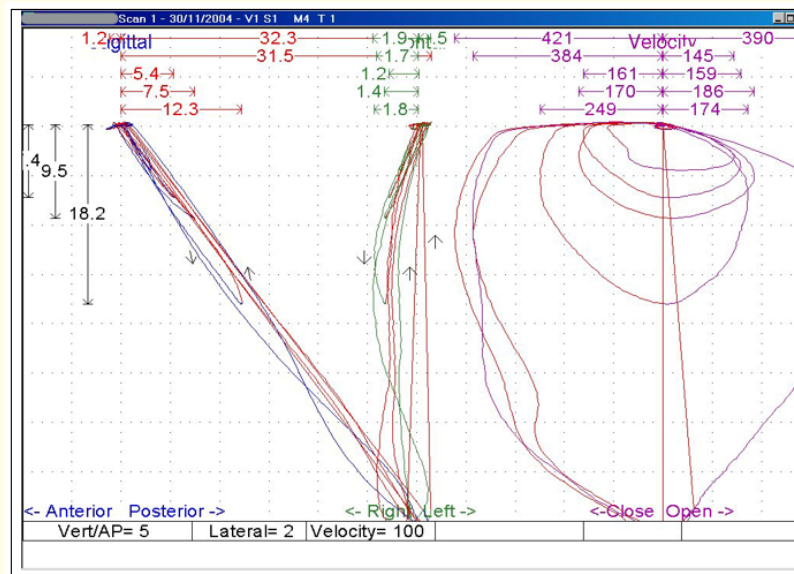
Figure 2E: Lateral cephalometric X-ray after treatment.

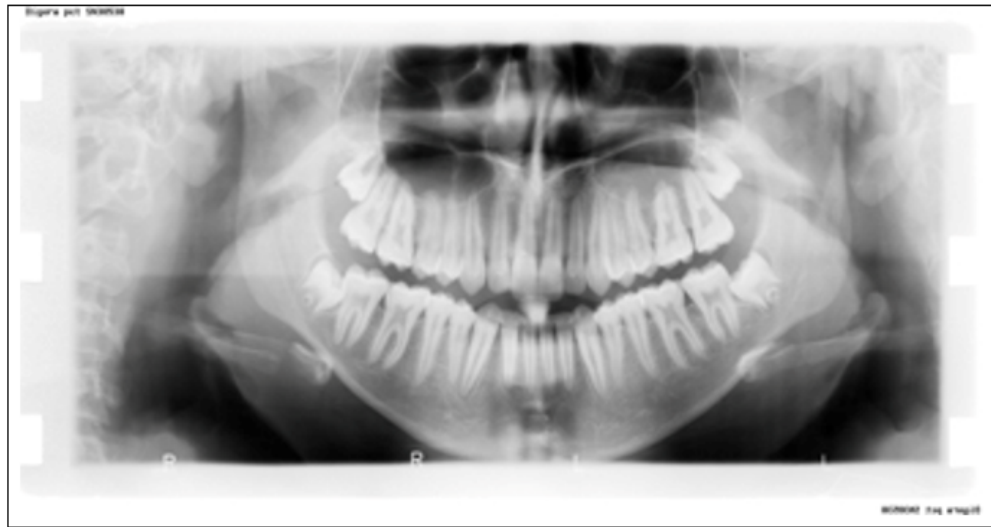

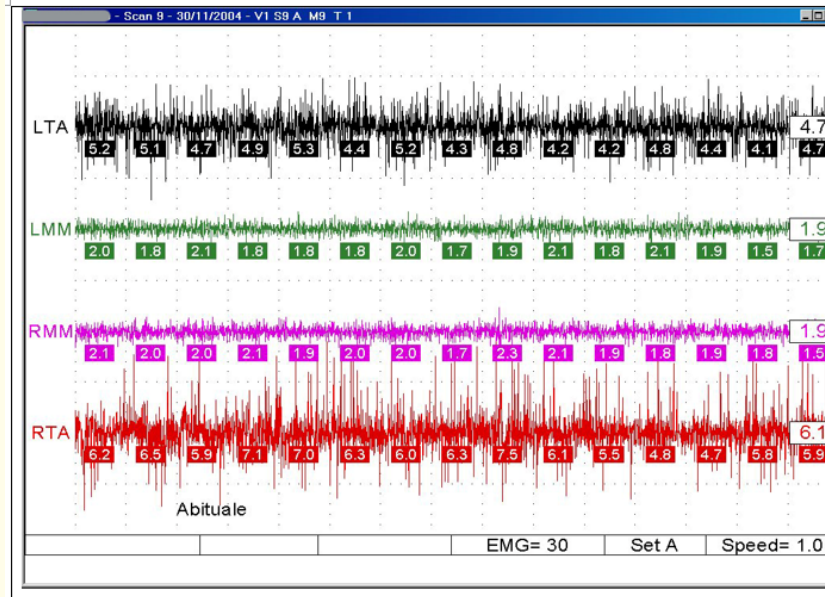
Figure 2F: Panoramic X-ray after treatment.

Results and Discussion

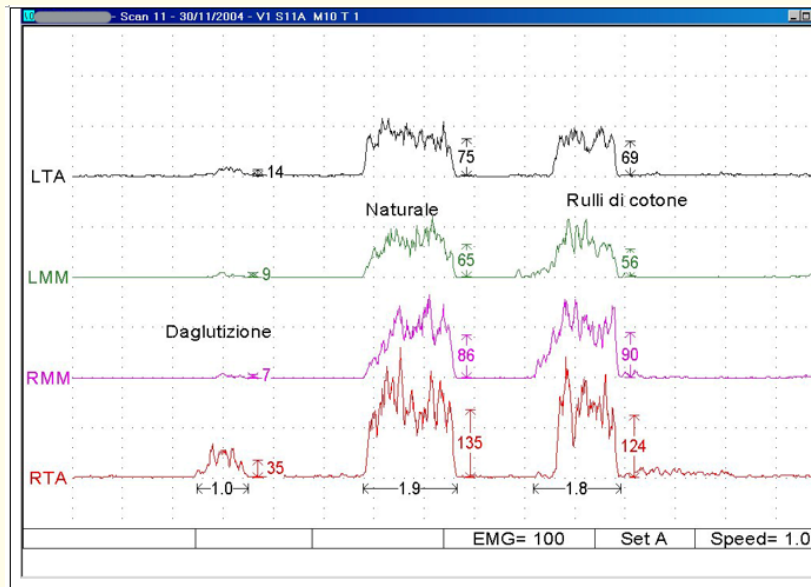
CMS scans pretreatment



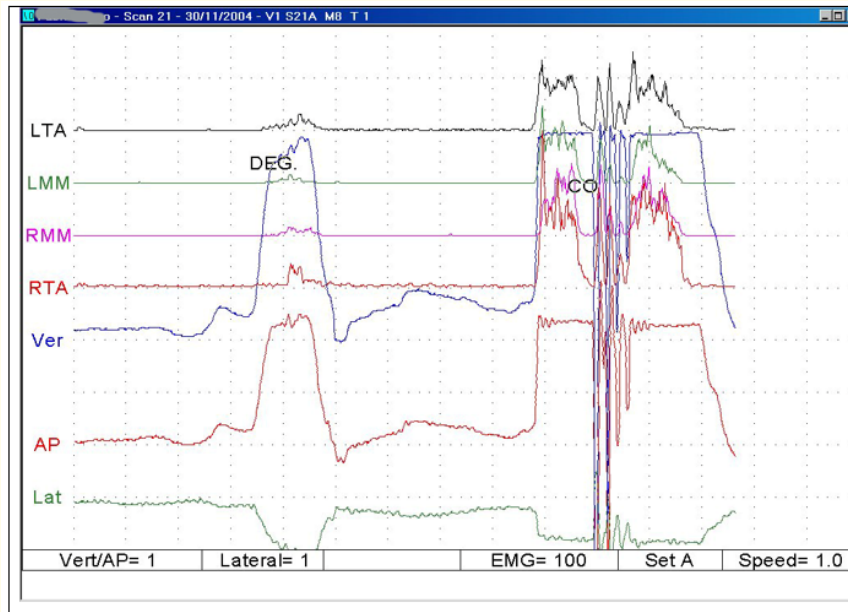
Scan 1: Pre-treatment. Within normal limits. Good overall mouth aperture, and tooth contact velocity was good.



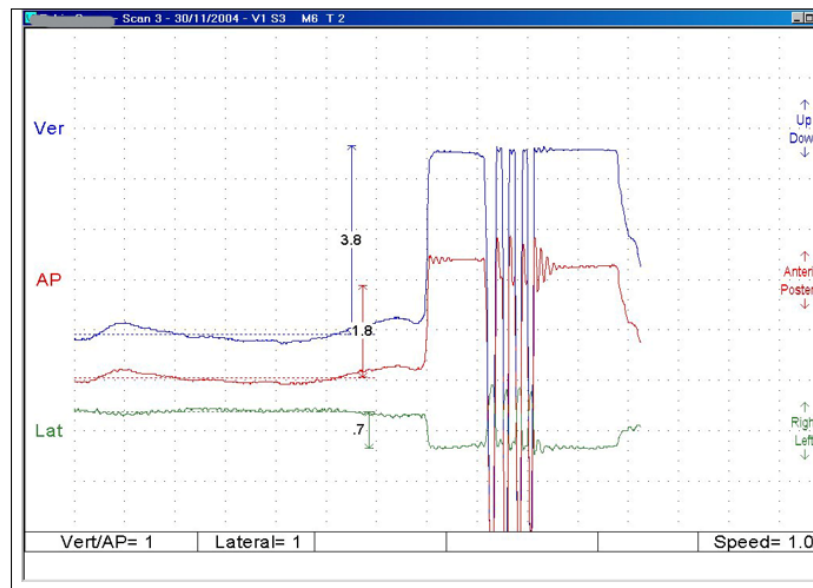
Scan 9: Pre-treatment. Before deconditioning with TENS. Left and right temporalis muscle output at rest was greater than the normal limits.



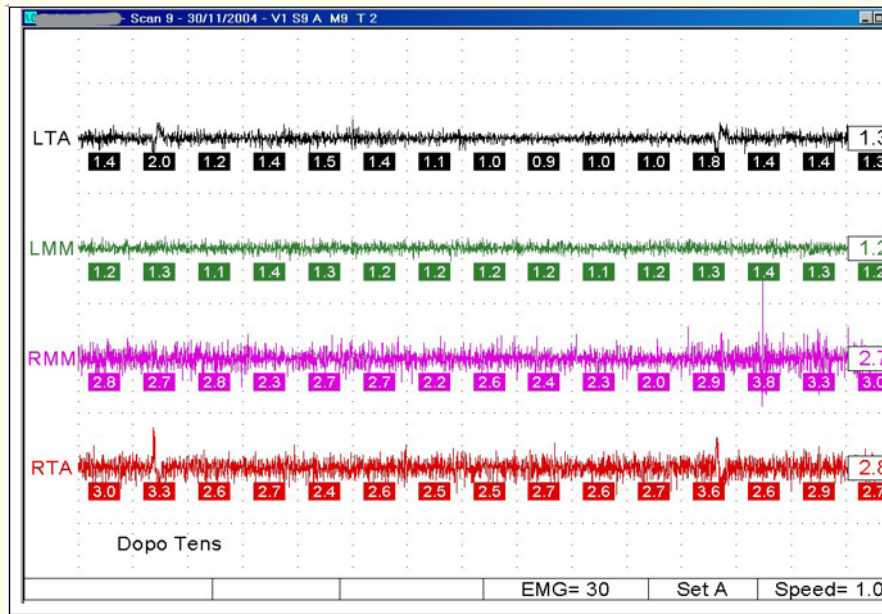
Scan 11: EMG during clench. Unbalanced muscle output for the temporalis muscles was noted.



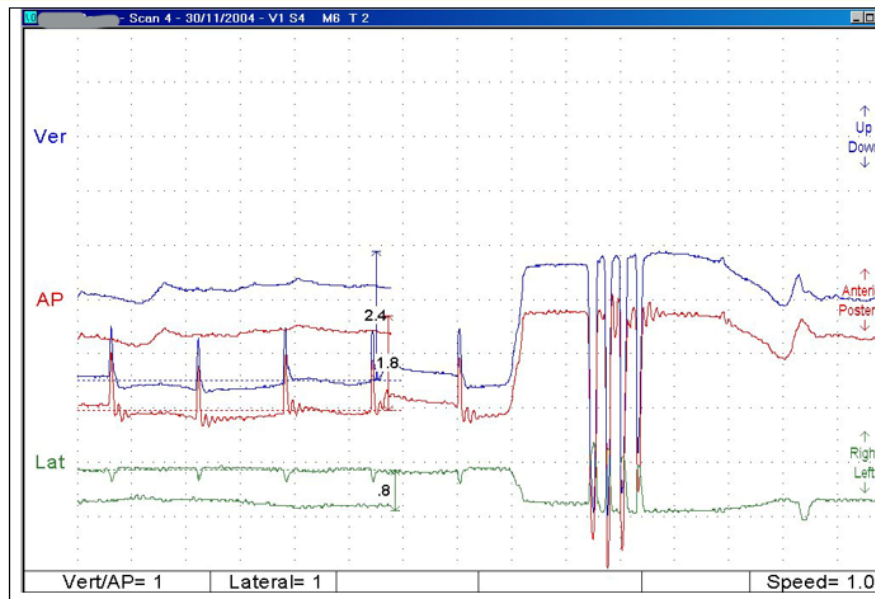
Scan 21: Pre-treatment. Filtered EMG during swallowing activity. The patient swallowed correctly and closed to centric occlusion (CO) during deglutition.



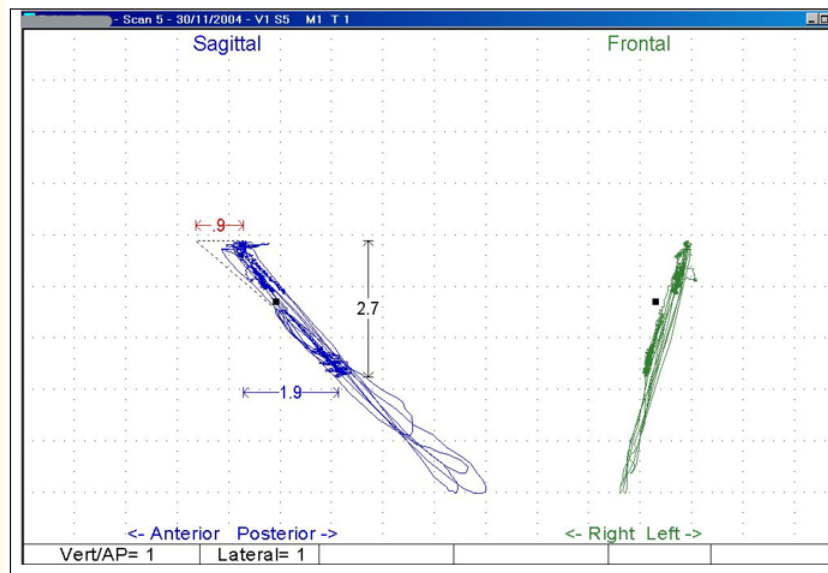
Scan 3: Pre-treatment. Vertical free-way space was 3.8 mm. The mandible moved left during closure from the habitual rest position.



Scan 9(10): Pre-treatment. SEMG after TENS. The muscles were relaxed and deconditioned.



Scan 4: Pre-treatment. Vertical free-way space was 2.4 mm.

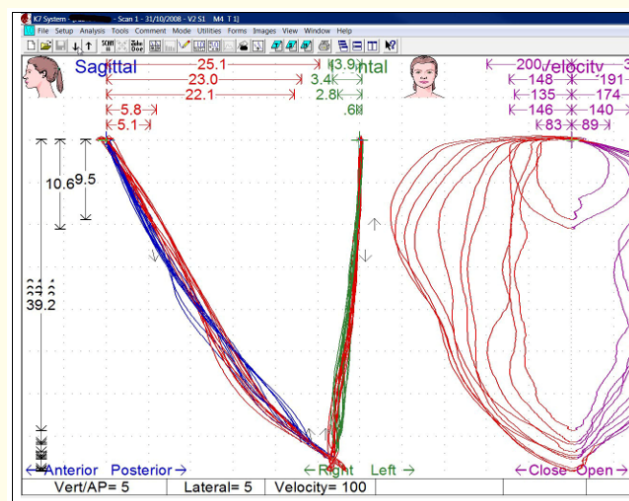


Scan 5 Pre-treatment. Overall rest position after TENS was not far from the habitual rest position before deconditioning. Only 0.9 mm of discrepancy was observed on the horizontal plane of occlusion.

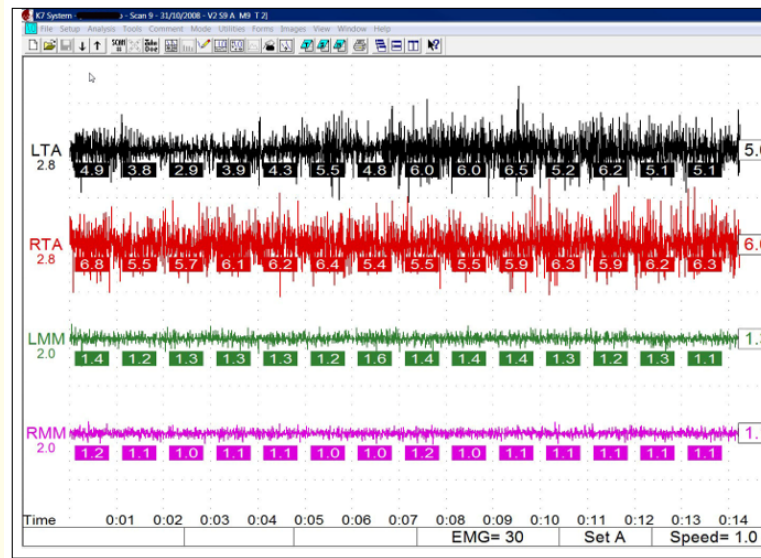
Figure A

The functional diagnostic analysis confirmed that the crowding of the lower incisor before treatment was beneficial for TMJ function. Had this not been present, the skeletal discrepancy would have been compensated by a major overload on the TMJ. The total amount of discrepancy (i.e. the overload the TMJ is supporting from occlusion) was a minimum of 0.9 mm. Aligning the lower arch without the proper overjet would have posteriorly displaced the mandibular condyle even more, with severe consequences for the TMJ. Diagnostic CMS confirmed that the case was purely orthodontic: on this horizontal plane of occlusion, the mandible should be only 0.9 mm in a more forward position. To achieve this, expansion and alignment of the upper arch only was the first step taken into consideration. Achieving a positive overjet can accommodate the lower alignment of the incisors substantially, without resulting in any premature deviating contact with the upper incisors. Bonding the lower arch for alignment seemed reasonable. The only extra space (primarily for the sagittal plane) needed was (1) 0.9 mm, as calculated from CMS; (2) about 2.5 mm for alignment of the lower incisors and (3) space for mandible growth. Because the alignment of the lower arch terminates just before the end of treatment (in this case at age 16), there is not much residual growth to worry about. Solving the lower crowding is calculated at about 2.5 mm on the sagittal plane, in reference to centric occlusion and on the occlusal plane. Therefore, a total of 3.5 mm of overjet is required to achieve proper alignment.

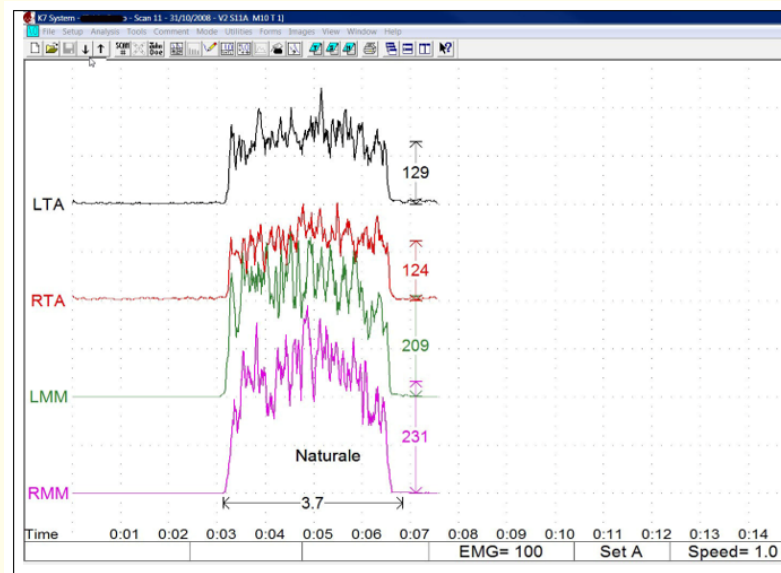
CMS 24 months after treatment



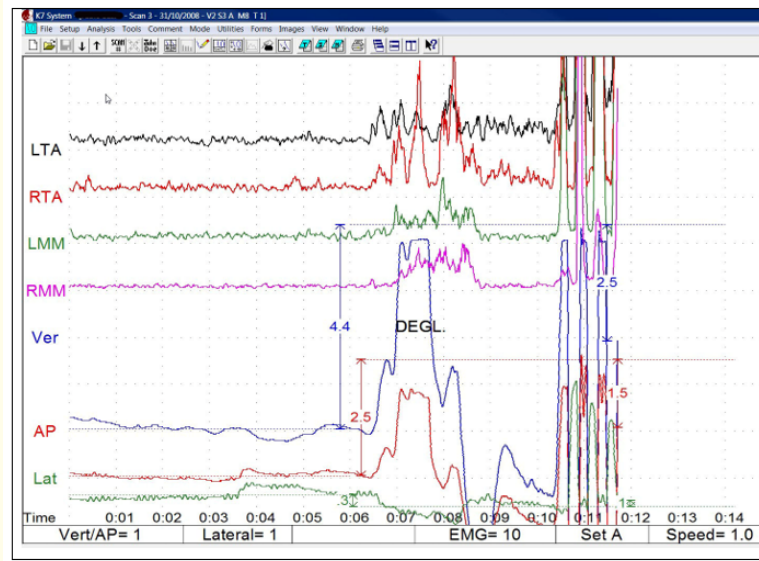
Scan 1: 24 months Post-treatment. Within normal limits. Good overall mouth aperture was observed, and tooth contact velocity was good. Compared with the pretreatment scan, the movements were more fluid, and there was less lateral deviation (0.8 mm).



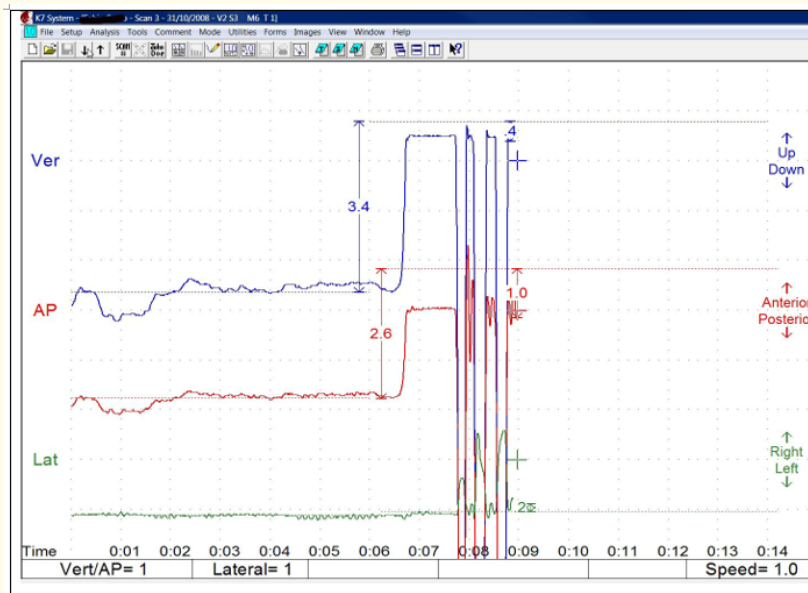Scan 9: 24 months Post-treatment. Before deconditioning with TENS. Left and right temporalis muscle output was greater than normal limits.



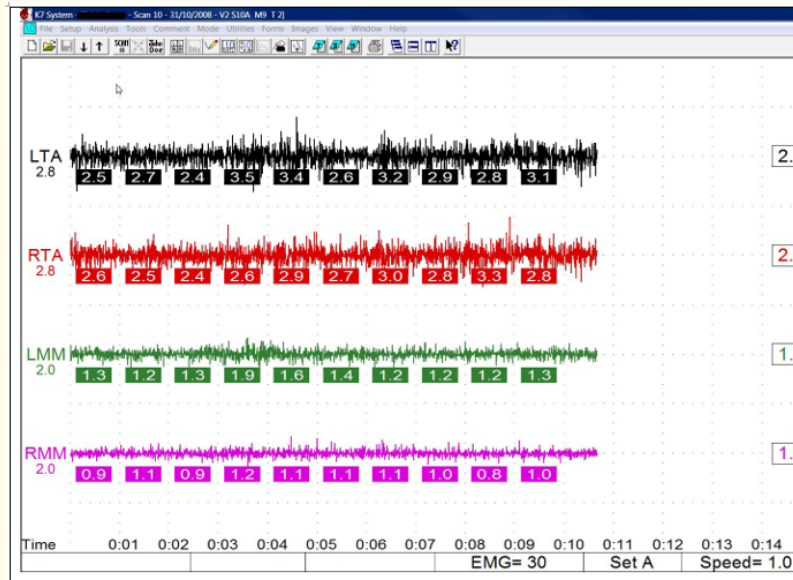
Scan 11: 24 months Post-treatment. EMG during clench. Balanced muscle output was achieved for the temporalis and masseters, with total output, compared with the much higher readings on the pretreatment scan.



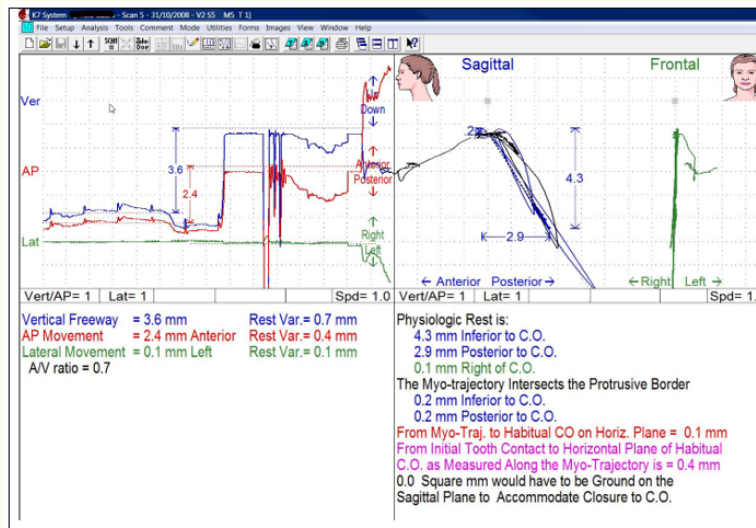
Scan 21(3): 24 months Post-treatment. Filtered EMG during swallowing activity. The patient swallowed correctly and closed to CO during deglutition.



Scan 3: 24 months Post-treatment. Free-way space was 3.4 mm. Compared with the pretreatment scan, no lateral deviation was present during closure from the habitual rest position.



Scan 10: 24 months Post-treatment. SEMG after TENS. Muscles were relaxed and deconditioned.



Scan 4/5: Splitscreen. 24 months post-treatment vertical free-way space was 3.6 mm. Overall rest position after TENS was not far from the habitual rest position before deconditioning. Only 0.2 mm of discrepancy was noted on the on horizontal plane of occlusion.

Figure B

Posttreatment CMS showed that the patient’s muscle function increased in both quality and force. The patient was followed up until the age of 17 years and was asymptomatic since upper maxillary expansion. There was very little chance of relapse due to residual growth. Posttreatment photos revealed that the patient’s over-bite was reduced to the minimum. This was a key factor for avoiding mandibular entrapment.

Cephalometric analysis

Sassouni cephalometric tracings before and after treatment showed mandibular advancement and an increase in lower facial height. The mandibular position relative to the cranium, pogonion to anterior arch, became negative after treatment readings (Figure 3-5).

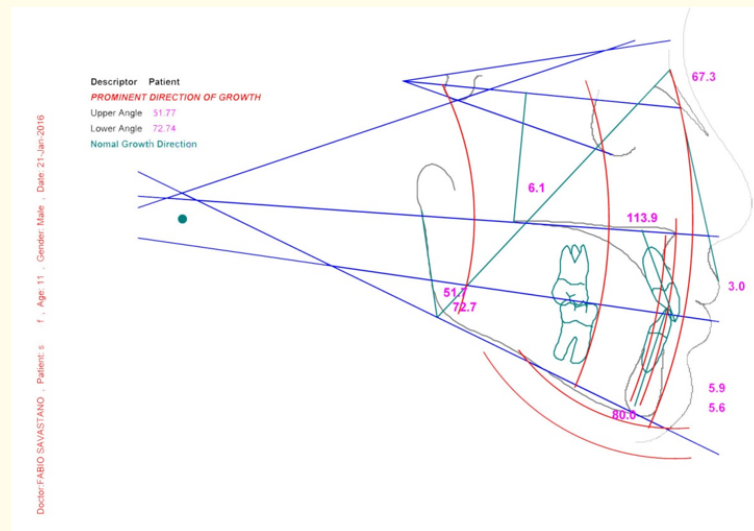


Figure 3: Sassouni cephalometric tracing, before treatment, age 11 years.

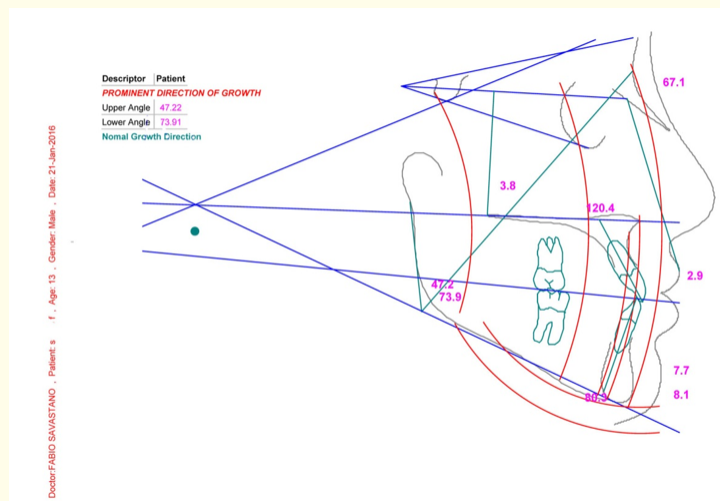


Figure 4: Sassouni cephalometric tracing, after treatment, age 13 years.

HORIZONTAL INTERPRETATIONS		HORIZONTAL INTERPRETATIONS	
Skeletal AP (Relation of Mandible to Maxilla)		Skeletal AP (Relation of Mandible to Maxilla)	
B point to the A Arc	5.97	B point to the A Arc	7.75
Pogonion to the ANS Arc	5.67	Pogonion to the ANS Arc	8.16
Strong Class III Relationship		Strong Class III Relationship	
Maxilla Length (Relative to the Cranium)		Maxilla Length (Relative to the Cranium)	
ANS to PNS	54.47	ANS to PNS	59.01
Cr Vertical Line to Anterior Arc	41.08	Cr Vertical Line to Anterior Arc	46.4
The Maxilla Is Long Posteriorly		The Maxilla Is Long Posteriorly	
Maxilla Position (Relative to the Cranium)		Maxilla Position (Relative to the Cranium)	
ANS to the Anterior Arc	-5.08	ANS to the Anterior Arc	-7.89
PNS to the Cr Vertical Line	-7.2	PNS to the Cr Vertical Line	-4.8
The maxilla is posteriorly positioned		The maxilla is posteriorly positioned	
Maxillary Lip Angle (Norm: 100 to 115 Degrees)	67.36	Maxillary Lip Angle (Norm: 100 to 115 Degrees)	67.12
Maxillary Lip Is Retruded		Maxillary Lip Is Retruded	
Mandible Length (Relative to the Cranium)		Mandible Length (Relative to the Cranium)	
Pogonion to Constructed Gonion	73.42	Pogonion to Constructed Gonion	80.7
Anterior Arc to Posterior Arc	72.55	Anterior Arc to Posterior Arc	72.9
Mandible Length Relative To Cranium Is Normal Anteriorly And Long Post		Mandible Length Relative To Cranium Is Normal Anteriorly And Long Post	
Mandible Position (Relative to the Cranium)		Mandible Position (Relative to the Cranium)	
Pogonion to the Anterior Arc	0.2	Pogonion to the Anterior Arc	-0.26
Constructed Gonion to the Posterior Arc	-5.52	Constructed Gonion to the Posterior Arc	-12.12
Mandible is in an undefined position relative to cranium		Mandible is in an undefined position relative to cranium	
VERTICAL INTERPRETATIONS		VERTICAL INTERPRETATIONS	
Skeletal Vertical (mm) (Relation between ANS-SOr and ANS-Me)	5.78	Skeletal Vertical (mm) (Relation between ANS-SOr and ANS-Me)	10.79
Open Bite Relationship		Open Bite Relationship	
Palatal Plane Inclination (deg) (Relative to Optic Plane)	6.18	Palatal Plane Inclination (deg) (Relative to Optic Plane)	3.86
The Bite Is Closing		The Bite Is Closing	

Figure 5: Results from Sassouni cephalometric tracings before and after treatment.

Superimposition (Figure 6) clearly demonstrated how mandibular freedom [27] was achieved to avoid mandibular entrapment (this was also confirmed by scans 4/5 tracings after treatment, as the path of closure corresponded to the neuromuscular trajectory with only 0.2 mm anterior on the horizontal plane of occlusion).

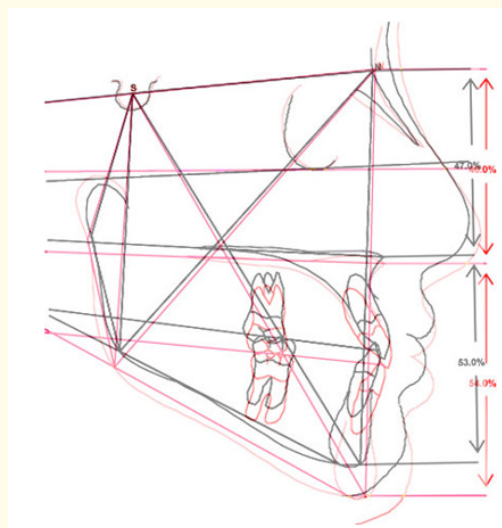


Figure 6: Superimposition on the S-N line before and after treatment (black indicates before treatment, red indicates after treatment).

Lower crowding was resolved without compromising TMJ function. Class I occlusion was achieved, and the patient had no signs or symptoms of TMJ dysfunction at the end of treatment and at follow-up at 10.5 years (Figure 7A-7C).

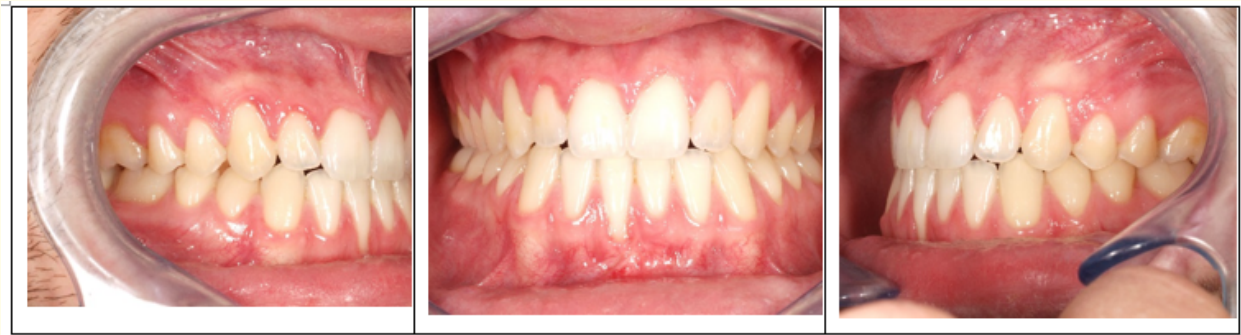

Figure 7A: Intra-oral photos 10.5 years after treatment.



Figure 7B: Extra-oral photos 10.5 years after treatment.

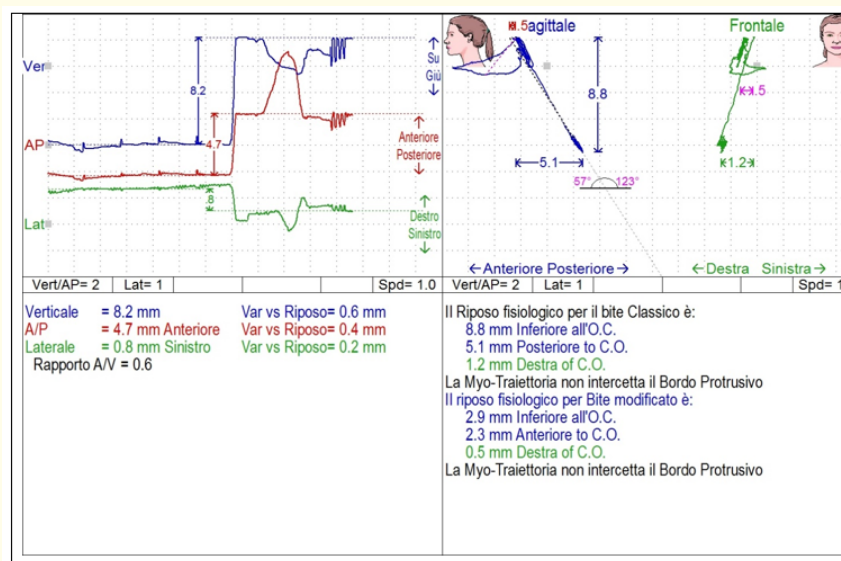


Figure 7C: Showing Scans 4/5 in split screen mode for CMS at follow-up 10.5 years after treatment. Habitual path of closure in overlapping neuromuscular trajectory.

Conclusion

Complete functional analysis with the complete K7 system is a very useful procedure for diagnosing patients with temporomandibular disorders. Information obtained before treatment avoids maneuvers that can compromise TMJ function. These technological aids offer an immense quantity of data, and the practitioner can adjust and personalize the procedures based on proper needs. Further investigation is needed to determine the importance of CMS in orthodontics.

Conflict of Interest

The author declares no financial interests and conflict of interest.

Bibliography

1. Bush FM, et al. "The relationship of TMJ clicking to palpable facial pain". *Journal of Craniomandibular Practice* 1.4 (1983): 43-48.
2. Egermark-Eriksson I, et al. "Prevalence of mandibular dysfunction and orofacial parafunction in 7-, 11- and 15-year-old Swedish children". *The European Journal of Orthodontics* 3.3 (1981): 163-172.
3. Egermark-Eriksson I, et al. "A long-term epidemiologic study of the relationship between occlusal factors and mandibular dysfunction in children and adolescents". *Journal of Dental Research* 66.1 (1987): 67-71.
4. Farrar WB. "Differentiation of temporomandibular joint dysfunction to simplify treatment". *Journal of Prosthetic Dentistry* 28.6 (1972): 629-636.
5. Farrar WB and WL McCarty. "Inferior joint space arthrography and characteristics of condylar paths in internal derangements of the TMJ". *Journal of Prosthetic Dentistry* 41.5 (1979): 548-555.
6. Farrar WB and WL McCarty. "A clinical outline of temporomandibular joint diagnosis and treatment". 7th edition. Montgomery, Ala. (2119 E.S. Blvd., Montgomery 36199); Normandie Study Group for TMJ Dysfunction (1982): 182.
7. Greene CS and JJ Marbach. "Epidemiologic studies of mandibular dysfunction: a critical review". *Journal of Prosthetic Dentistry* 48.2 (1982): 184-190.
8. Weinberg LA. "The role of stress, occlusion, and condyle position in TMJ dysfunction-pain". *Journal of Prosthetic Dentistry* 49.4 (1983): 532-545.
9. Weinberg LA and JK Chastain. "New TMJ clinical data and the implication on diagnosis and treatment". *Journal of the American Dental Association* 120.3 (1990): 305-311.
10. Weinberg LA and LA Lager. "Clinical report on the etiology and diagnosis of TMJ dysfunction-pain syndrome". *Journal of Prosthetic Dentistry* 44.6 (1980): 642-653.
11. Robert R Jankelson, et al. "Neuromuscular dental diagnosis and treatment". *American Journal of Orthodontics and Dentofacial Orthopedics* 99.3 (1991): 283-284.
12. Jankelson B. "Neuromuscular aspects of occlusion. Effects of occlusal position on the physiology and dysfunction of the mandibular musculature". *Dental Clinics of North America* 23.2 (1979): 157-168.
13. Jankelson B. "Measurement accuracy of the mandibular kinesiograph--a computerized study". *Journal of Prosthetic Dentistry* 44.6 (1980): 656-666.

14. Jankelson B. "Three-dimensional orthodontic diagnosis and treatment. A neuromuscular approach". *Journal of Clinical Orthodontics* 18.9 (1984): 627-636.
15. Jankelson B., et al. "The physiology of the stomatognathic system". *Journal of the American Dental Association* 46.4 (1952): 375-386.
16. Jankelson B., et al. "Kinesiometric instrumentation: a new technology". *Journal of the American Dental Association* 90.4 (1975): 834-840.
17. Weinberg LA. "The role of muscle deconditioning for occlusal corrective procedures". *Journal of Prosthetic Dentistry* 66.2 (1991): 250-255.
18. Hugger A., et al. "Surface electromyography of the masticatory muscles for application in dental practice. Current evidence and future developments". *International Journal of Computerized Dentistry* 11.2 (2008): 81-106.
19. Hugger S., et al. "Surface EMG of the masticatory muscles (Part 3): Impact of changes to the dynamic occlusion". *International Journal of Computerized Dentistry* 16.2 (2013): 119-123.
20. Schindler HJ and W Blaser. "[T.E.N.S., a myofunctional concept for oral rehabilitation]". *Quintessenz* 33.11 (1982): 2181-2191.
21. Schindler HJ., et al. "[T.E.N.S. (transcutaneous electroneurostimulation), a myofunctional concept for oral rehabilitation (II)]". *Quintessenz* 33.2 (1982): 295-307.
22. Sgobbi de Faria CR and F Berzin. "Electromyographic study of the temporal, masseter and suprahyoid muscles in the mandibular rest position". *Journal of Oral Rehabilitation* 25.10 (1998): 776-780.
23. Forrester SE., et al. "Neuromuscular function in healthy occlusion". *Journal of Oral Rehabilitation* 37.9 (2010): 663-669.
24. Monaco A., et al. "Surface electromyography pattern of human swallowing". *BMC Oral Health* 8 (2008): 6.
25. Wozniak K., et al. "Surface electromyography in orthodontics - a literature review". *Medical Science Monitor* 19 (2013): 416-423.
26. Wozniak K., et al. "The electrical activity of the temporal and masseter muscles in patients with TMD and unilateral posterior cross-bite". *BioMed Research International* (2015): 259372.
27. Savastano F. "Applying neuromuscular techniques in the orthodontic setting: a case report". *South European Journal of Orthodontics and Dentofacial Research* 4.2 (2017): 20-31.

Volume 19 Issue 10 October 2020

©All rights reserved by Fabio Savastano and Giulia Savastano.